

# The Role of Topical Vitamin E in Scar Management: A Systematic Review

Volkan Tanaydin, MD; Jurek Conings, MD; Masoud Malyar, BSc; René van der Hulst, MD, PhD; and Berend van der Lei, MD, PhD

Aesthetic Surgery Journal  
2016, Vol 36(8) 959–965  
© 2016 The American Society for  
Aesthetic Plastic Surgery, Inc.  
Reprints and permission:  
journals.permissions@oup.com  
DOI: 10.1093/asj/sjw046  
www.aestheticsurgeryjournal.com

**OXFORD**  
UNIVERSITY PRESS

## Abstract

**Background:** The practice of prescribing vitamin E after surgery for scar prevention and treatment is widespread and increasingly popular among both the public and clinicians. However, very little evidence exists for this “ritual.”

**Objectives:** This review was undertaken to critically analyze the current literature about the effect of vitamin E on treating scars.

**Methods:** The Cochrane, Medline, and PubMed databases were searched based on the Preferred Reporting Items for Systematic Review and Meta-Analysis Protocols (PRISMA-P). The studies and levels of recommendation were graded according to the American Society of Plastic Surgeons (ASPS) criteria. Only prospective studies were included.

**Results:** Only six studies met the inclusion criteria. Of these six included studies, three reported a significant improvement in the cosmetic appearance of scars when using vitamin E: one study used topical vitamin E in white children as monotherapy, and two studies used vitamin E in an adult population as combination therapy. The other three selected studies showed no significant improvement in scar appearance when using topical vitamin E as monotherapy. Two of the six included studies reported adverse events of vitamin E application: contact dermatitis and increased incidence of itching and rash.

**Conclusions:** We conclude that there is not yet sufficient evidence that monotherapy with topical vitamin E has a significant beneficial effect on scar appearance to justify its widespread use. Further prospective studies with vitamin E monotherapy and/or combination therapy are warranted to draw better conclusions regarding the value of vitamin E in the management of scar healing.

## Level of Evidence: 2



Accepted for publication February 22, 2016; online publish-ahead-of-print March 14, 2016.

Scar treatment has always been and still is an important topic for plastic surgeons, because poorly healed, clearly visible scars can have significant negative effects on cosmesis and patient self-esteem. In recent years, several scar treatment strategies have been developed and recommended. Some of these treatment options include only one modality,<sup>1</sup> whereas others combine several modalities such as surgery,<sup>2</sup> laser treatment,<sup>3</sup> radiation therapy,<sup>4,5</sup> pressure therapy,<sup>6</sup> and cryotherapy.<sup>7</sup> In addition, several pharmaceutical agents are recommended to treat scars, such as topical vitamin E, steroids, antioxidants, moisturizers, and so on. It has been demonstrated that a significant proportion of medical professionals and many patients believe that treatment of scars with topical vitamin E can help to improve the cosmetic outcome of a scar.<sup>8</sup> Vitamin E, or tocopherol, is the most important lipid-soluble membrane-bound antioxidant in the body.<sup>9</sup> It consists

out of eight antioxidants, from which the stereoisomers are derived from the tocopherols and the tocotrienols. Among these forms,  $\alpha$ -tocopherol has the most potent biological activity, because it is the only form maintained in the human body. Vitamin E acts as an anti-inflammatory agent and affects the remodeling of scars by interacting with the phospholipids in cell membranes, inducing molecular packing and maintaining the stability of biologic membranes.<sup>10,11</sup>

From the Department of Plastic Surgery, Maastricht University Medical Center, Maastricht, The Netherlands.

### Corresponding Author:

Dr Volkan Tanaydin, Maastricht University Medical Center,  
P. Debyelaan 25, Maastricht, Limburg 6229 HX, The Netherlands  
E-mail: v.tanaydin@gmail.com

Vitamin E is used cosmeceutically to accelerate wound healing, to prevent hypertrophic scarring, and to decrease pruritis.<sup>12</sup> However, to date, there is neither a consensus nor good scientific evidence for the use of vitamin E in the treatment of scars. Therefore, this review was undertaken to evaluate the evidence from prospective studies regarding the effect of topical vitamin E on the outcome of scars.

## METHODS

### Search Strategy

The Cochrane, Medline, and PubMed databases were searched in January 2016 using possible combinations and search terms covering the use of vitamin E in the treatment and management of scars. The following search terms were used to: **scar, hypertrophic scar, keloid, vitamin E, tocopherol, tocotrienol, treatment, topical, topical administration, and topical use**. Additional studies were identified and selected by searching reference lists from the selected articles. No limits were applied for year of publication or publication status.

### Study Selection Criteria

We evaluated all types of studies reporting the treatment of scars using topical vitamin E. There were no limitations on the type of studies or the year of publication. The articles were published between 1951 and 2016. There was a limit for language; only articles in English, German, Dutch, Turkish, and Polish were included. In the grey literature search, we did not find any articles that could be included in this review. All the search terms were used as a medical subject heading (MeSH) term, except “topical,” because it is not a valid MeSH term. Two reviewers screened the identified records from the search for eligibility in an unblinded standardized manner. After the initial search, there was a result of 70 hits. The initial inclusion was based on the title and abstract. Articles that were excluded were reviews on scar treatment (7), review on scars caused by burns (1), therapy other than vitamin E for scars (10), animal studies (9), effect of vitamin E on events other than scarring the skin (23), letter to the editor (1), questionnaire (1), and articles not in English, German, Dutch, Turkish, or Polish language (9). Nine articles were found eligible after the initial inclusion. The reviewers read each of these nine articles to confirm that they met the inclusion criteria for this review.

Because of the limited number of articles published about vitamin E, we included all studies with topical application of vitamin E, whether used as monotherapy or combination therapy, in relation to wound healing or scar management. In the end, a total of six articles were included in this review after excluding articles without scientific value. We used two independent investigators to minimize the possibility of

rejecting relevant studies. Any disputes in data extraction were resolved by a third independent reviewer.

### Presentation of Data

This review was written using the PRISMA-P (Preferred Reporting Items for Systematic Review and Meta-Analysis Protocols) statement, which is a checklist of items to include when reporting a systematic review.

### Methodological Quality Assessment

The level of evidence of the extracted studies was graded according to the American Society of Plastic Surgeons (ASPS) Evidence Rating Scales. This classification assigns each article to a corresponding level of evidence ranging from I (highest) to V (lowest). Besides this classification, a practice recommendation was provided according to the ASPS Grade Recommendation Scale.

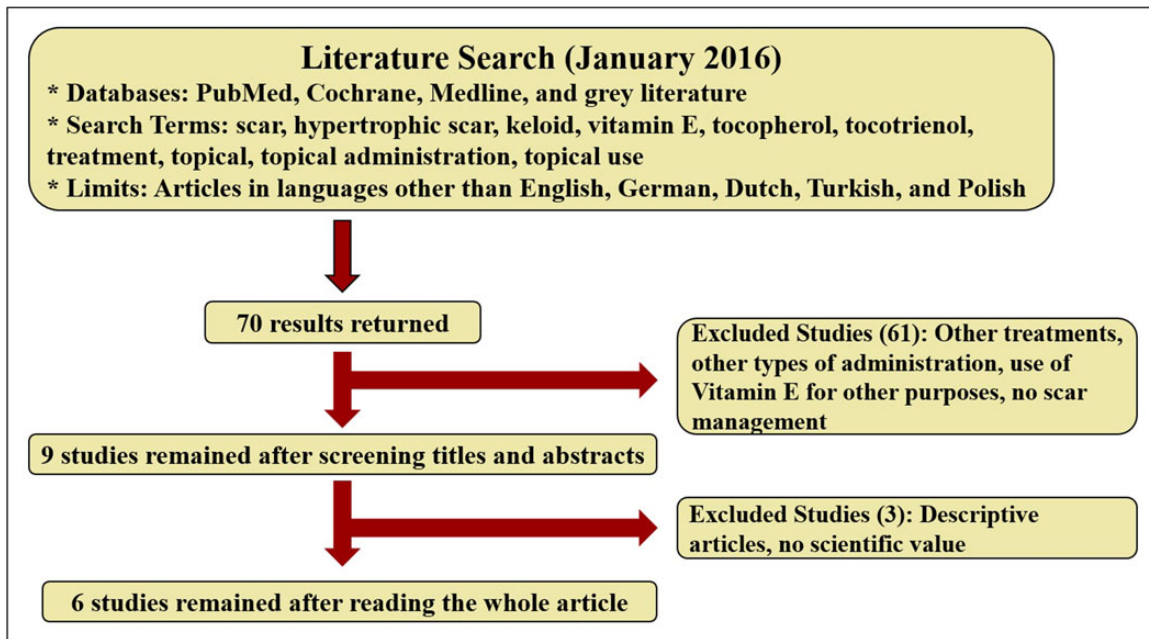
## RESULTS

### Study Characteristics

Our research yielded a total of 70 studies in the Cochrane, Medline, and PubMed databases. Of these 70 studies, 61 were excluded after reviewing the title and abstract. Studies were excluded either because of the use of vitamin E as a non-topical treatment, or if they were conducted for purposes other than scar treatment or other treatment modalities. Ultimately, after screening the full article, we could only include six studies for review (Figure 1). These included studies were conducted in a prospective manner using topical vitamin E, either in monotherapy or combination therapy, and had a level of evidence of type II, according to the ASPS Evidence Rating Scale for Therapeutic Studies.<sup>13</sup> The length of follow-up in each of the six studies was quite different, ranging from 8 weeks to 1 year after treatment. We have conducted a review of funding resources for the included studies and found that only Khoo et al’s work was funded by the University Sains Malaysia ShortTerm Grant. The authors have no conflicts of interest to declare.

### Patient Characteristics

The size of the study population (n) of the six included studies ranged from 15 to 428 patients with three times as many male than female participants. Only one study was conducted among children,<sup>14</sup> and the other five studies were conducted among adults. Inclusion and/or exclusion criteria were only mentioned in three out of the six studies.<sup>11,14,15</sup> None of the studies used the Fitzpatrick scale to determine the skin type of investigated patients, and only two of the studies described the racial appearance of their study population (white children and Malaysians).<sup>14,15</sup>



**Figure 1.** PRISMA-P flowchart of included and excluded studies.

## Treatment

In this review, we focus on vitamin E as a topical agent. The six selected studies described vitamin E as a monotherapy as a gel or cream or as combination therapy with a silicone sheet or hydrocortisone, or with silicone and vitamin E in collodion (a syrupy solution). Next to the difference in local application, each study used a different concentration of vitamin E (Table 1).

## Effectiveness and Recurrence

Each of the six included studies assessed the scars in a subjective manner using either the **Vancouver Scar Scale (VSS)**,<sup>16</sup> **Patient and Observer Scar Assessment Scale (POSAS)**,<sup>17</sup> **Visual Analogue Scale (VAS)**,<sup>18</sup> or the **Scott-Huskisson Scale**,<sup>11</sup> or simply by taking photographs. Only one study used a laser Doppler imager (LDI) as an objective evaluation.<sup>15</sup>

Of the six included studies, three reported a significant improvement in cosmetic appearance when using vitamin E. Of these three studies, only the study of Zampieri et al<sup>14</sup> used topical vitamin E as monotherapy in a study population consisting of white children ranging from 2 to 9 years of age. The two other studies demonstrated the effect of the use of vitamin E in combination therapy in an adult population: Palmieri et al<sup>11</sup> used vitamin E in combination therapy with silicone gel sheets, and Perez et al<sup>19</sup> used vitamin E in combination with hydrocortisone and silicone sheets. These last two studies had no preventive interventions in the treatment of (hypertrophic) scars or keloids, compared with the study of Zampieri et al.<sup>14</sup> Moreover, in the study of Zampieri

et al, vitamin E was applied both in the preoperative and postoperative periods, whereas it was applied only in the postoperative period in all other studies. In demonstrating a positive effect of vitamin E on wound healing, these three studies all used a subjective method to assess the scars (either one or more from the VSS, VAS, Scott-Huskisson scale, or simply by taking photographs).

The three other selected studies among the six included in this review showed no beneficial effect when using topical vitamin E; there was no significant improvement in scar appearance. The subjective methods used to assess scar healing and appearance in these three studies were POSAS, VAS, and simply by taking photographs. No improvement could be detected at all: only one of these three studies, the study by Khoo et al,<sup>15</sup> used an objective method to document scar improvement (LDI), and they did not find any objective change in the vascularity of the scars.

## Complications

Two of the six included studies described adverse events of the application of topical vitamin E: the study by Baumann et al<sup>20</sup> described a contact dermatitis in up to 33% of the treated patients, and the study by Jenkins et al<sup>21</sup> mentioned an increased incidence of itching and rash. The other four included studies did not witness any adverse effects.<sup>11,14,15,19</sup>

## DISCUSSION

Topical vitamin E is a frequently prescribed topical agent in the treatment of scars, despite the lack of evidence of its

Table 1. Characteristics of the Included Studies

Study	Study Type	No. of Patients	Gender (m/f)	Race	Age (yrs)	Area of Interest	Dosage Vitamin E	Use, Frequency, and Duration	Follow-up	Assessment Type	Results	LoE*
Zampieri et al, 2010 <sup>14</sup>	Prospective, single-blinded	428	319/109	White	2-9	Incision for inguinal surgery	N/R	At least 15 days, twice a day, before surgery At least 30 days, twice a day, after surgery	Follow-up 10 days after end of treatment and after 6 months	Subjective - VSS	Study group reported no keloids (p<.05) or wound infection	II
Baumann et al, 1999 <sup>20</sup>	Prospective, double-blinded	15	N/R	White	N/R	Skin cancer removal surgery (Mohs)	320 IU/gm	Twice daily for 4 weeks	Follow-up at weeks 1, 4, and 12 months	Subjective - Evaluation of appearance by physician and patient - Photographs	Topically applied vitamin E does not help improve cosmetic appearance	II
Jenkins et al, 1986 <sup>21</sup>	Prospective, double-blinded	111	N/R	White	3-20	Operative procedure for postburn contractures	200 units/gram	Three times a day with a massage of three minutes continued for 120 days	Follow-up at 1 month, 4 months, and 1 year	Subjective - Evaluation by research nurse - Photographs	No significant difference of scar thickness	II
Khoo et al, 2011 <sup>15</sup>	Prospective, double-blinded	85	75/10	Malaysian (88.4%), other (11.6%)	16-59	Surgical scars	5% tocotrienol 71.7% deionized water	Twice a day for 6 weeks starting at 2 weeks after surgery	Follow-up at 0, 2, 6, and 16 weeks following the onset of topical application	Subjective - POSAS - VAS Objective - LDI	No significant effect on appearance and vascularity of scars	II
Palmieri et al, 1995 <sup>11</sup>	Prospective, single-blinded	80	N/R	White	18-63	Postsurgical/burn	Silicone gel sheets with vitamin E (3%, 5 g/silicon sheet)	4 to 8 weeks	Follow-up at 4 and 8 weeks	Subjective - Scott-Husskison scale - Photographs MPR LoE	Vitamin E added to silicone sheets scored better results than simple silicone plate alone	II
Perez et al, 2010 <sup>19</sup>	Prospective	30	N/R	White	>18	Keloids and hypertrophic scars	HSE (0.5%) and onion extract	Duration of 16 weeks	Follow-up at 4, 8, 12, and 16 weeks	Subjective - VAS Objective - MPR	HSE had a significant MPR in different fields.	II

HSE, hydrocortisone, silicone, and vitamin E lotion; LDI, laser Doppler imaging; LoE, level of evidence; MPR, mean percent reduction (volume, length, induration, erythema, pigmentation, tenderness, pain, and itching); N/R, not reported; POSAS, Patient and Observer Scar Assessment Scale; VAS, Visual Analogue Scale; VSS, Vancouver Scar Scale. \* As determined by the authors using the ASPS Evidence Rating Scales.

presumed effect. In the study of Curran et al,<sup>8</sup> which evaluated the basic scientific knowledge of vitamin E among doctors, nurses, pharmacists, and students, nearly 68% of the patients had the opinion that vitamin E could improve the cosmetic appearance of scars and 25% would recommend vitamin E to patients to improve the cosmetic appearance of their scars. In addition, 22% of patients had used vitamin E themselves for scars. Based on our review, we conclude that there has not yet been sufficient evidence that monotherapy with topical vitamin E has a significant beneficial effect on scar appearance: only three out of our six selected studies reported some beneficial effect of vitamin E. In addition, the topical application of vitamin E might also result in side effects (itching, contact dermatitis, rash), making it detrimental on the final cosmetic outcome under certain circumstances.

When vitamin E is used in combination therapy, there seems to be a positive effect on scar healing. In two selected articles in our review, vitamin E was used as combination therapy and reported an improvement in cosmetic appearance: Perez et al<sup>19</sup> used vitamin E in a combination therapy with hydrocortisone and silicone, and Palmieri et al<sup>11</sup> used vitamin E in a combination therapy with silicone sheets containing vitamin E. However, whether vitamin E has a significant role in this positive effect is not quite clear from these studies, because both additional components (hydrocortisone and silicone sheets) are known to have a beneficial effect in scar healing and appearance.<sup>22,23</sup> To date, evidence is limited for the use of topical steroids for scar management, but there is a broad consensus that the use of intralesional corticosteroids is efficacious. The use of intralesional corticosteroids is first-line

therapy for the treatment of keloids and second-line therapy for the treatment of hypertrophic scars if other easier treatments have not been efficacious.<sup>24</sup>

According to two systematic reviews about silicone gel therapy, there is weak evidence of a benefit of silicone gel sheeting to prevent abnormal scarring in high-risk individuals.<sup>25</sup> However, in burn wounds, the efficacy of silicone gel showed significant improvements.<sup>26</sup> Therefore, it seems that steroids and/or silicone therapy have some effect on scar healing, and the improved scar healing that was observed in the articles of Perez et al<sup>19</sup> and Palmieri et al<sup>11</sup> cannot be solely ascribed to vitamin E.

Zampieri et al<sup>14</sup> provided significant results regarding the prevention of scar formation. Topical vitamin E was applied both preoperatively and postoperatively, resulting in a significant beneficial effect and improved wound healing on the final cosmetic appearance of the scars using the VSS scale. However, the exact composition of their commercially available product containing vitamin E is unknown. Despite the observed positive effect in this study, it is questionable whether these results can also be obtained in a general population. The study population of Zampieri et al<sup>14</sup> consisted of white children, a race less prone to develop hypertrophic scars or keloids, and it is known that keloids tend to develop more often in people with a darker skin and that they are never seen in people without skin pigmentation (albinos).<sup>27,28</sup> Moreover, the age of the study population of Zampieri et al<sup>14</sup> varied between 2 and 9 years of age, although people between the ages of 10 and 30 are more prone to develop keloids.<sup>29,30</sup>

Unfortunately none of the six included studies used in our review used the Fitzpatrick skin scale or a similar skin scale to assess the skin type of their study population. This would have given a better objective impression of the effects of topical vitamin E in patients with an increased risk for hypertrophic scars and keloids.

An underexposed part of scar treatment is the use of scar massage. This could happen consciously by a therapist or with massage tips given to patients or unconsciously when you apply an emollient or moisturizing agent to a scar. Scar massage may have positive benefits on scars, leading to increased scar pliability, decreased scar banding, and some relief of swelling and induration.<sup>24,31</sup> In a review conducted by Shin et al<sup>32</sup> concerning the role of massage in scar management of 144 patients who underwent scar massage therapy, 65 patients (45.1%) experienced improvement in one or more of the following: POSAS, VSS, mood, range of motion, pruritis, pain, depression, and anxiety.<sup>32,33</sup> Additionally, massage could also have a positive effect on anxiety levels, depression, and the overall mood of patients.<sup>31,32,34</sup> Adverse effects of scar massage therapy have also been reported: it could lead to a break in the epidermis, bleeding, infections, wound dehiscence, graft failure, irritation from friction, and dermatitis caused by hypersensitivity to the used emollient.<sup>24,32,34</sup>

Early massage of the scar should also be avoided according to evidence in a mouse model, in which massage of the scar in the early phases of wound healing promoted hypertrophic scarring.<sup>32,35</sup> Although various studies in the literature acknowledge the effect of massage therapy on scars, an evidence-based recommendation for implementing this technique cannot be made, because none of these studies have been validated.<sup>24,32</sup>

Although there is no clear evidence that the topical application of vitamin E may cause significant harm, several side effects of topical vitamin E have been reported since its introduction, such as contact dermatitis,<sup>36-38</sup> erythema multiforme-like eruptions,<sup>37,39</sup> and urticarial eruptions.<sup>37</sup> In our review, only two out of the six selected studies reported adverse events: Baumann et al<sup>20</sup> described contact dermatitis after the topical use of vitamin E in 33% of the patient population, and Jenkins et al<sup>21</sup> reported an increased incidence of itching and rash. In the Jenkins study, the incidence of these side effects is not known, because the authors excluded all patients in their study who developed adverse effects. Widgerow et al<sup>40</sup> found that the early use of vitamin E to treat scars can result in a reduction of the tensile strength of the wound, which could lead to broad and stretched scars.

In recent decades, several scar assessment scales have been developed. However, none of them has completely met the clinimetric requirements. Although many authors consider the POSAS to be most suitable for scar assessment, a solid gold standard for objective scar assessments is still lacking<sup>41</sup> and actually wanted. All selected studies in our review used subjective methods to measure scar changes, with the exception of Khoo et al,<sup>15</sup> which used an objective method (LDI) to measure scar changes.

Limitations of this review include the small number of studies published on this topic, the quality and level of evidence of the collected studies, the lack of standardized outcome measures, and the variation in the study population (children vs adults).

Vitamin E, or tocopherol, is a substance often found in scar creams and also recommended by medical personnel in hospitals or by general practitioners. The general consensus about the application of a vitamin E-based cream or emollient is that it would lead to beneficial scar healing. Doing research on this topic eventually leads us to the idea that there was no comprehensive review performed on the scientific evaluation of the use of vitamin E on scar treatment. Therefore this literature review on the effects of vitamin E on scar treatment is, to our knowledge, the only review conducted to date that concentrates solely on the topical administration of Vitamin E on scars.

## CONCLUSIONS

Although the practice of prescribing vitamin E after surgery is widespread, there is a paucity of evidence that vitamin E

has any beneficial effect. This systematic review regarding the effectiveness of topical vitamin E on scars and wound healing resulted in a limited series of six studies fulfilling the criteria of evaluating the effectiveness of vitamin E in a prospective manner. Based on this review, we conclude that there is not yet sufficient evidence that monotherapy with topical vitamin E has a significant beneficial effect on scar appearance to justify its widespread use. Only one of the six selected studies found improved scar appearance/healing when using vitamin as monotherapy, and two studies found efficacy when using vitamin E in combination therapy. Further prospective studies regarding vitamin E monotherapy and/or combination therapy are therefore warranted to draw better conclusions regarding the value of vitamin E in the management of scar healing.

### Disclosures

The authors declared no potential conflicts of interest with respect to the research, authorship, and publication of this article.

### Funding

The authors received no financial support for the research, authorship, and publication of this article.

### REFERENCES

1. Reish RG, Eriksson E. Scars: a review of emerging and currently available therapies. *Plast Reconstr Surg*. 2008;122(4):1068-1078.
2. Son D, Harijan A. Overview of surgical scar prevention and management. *J Korean Med Sci*. 2014;29(6):751-757.
3. Cavalié M, Sillard L, Montaudié H, et al. Treatment of keloids with laser-assisted topical steroid delivery: a retrospective study of 23 cases. *Dermatol Ther*. 2015;28(2):74-78.
4. Willett M, Handfield K, Marquart J. Multimodal keloid therapy with excision, application of mitomycin C, and radiotherapy. *Dermatol Surg*. 2014;40(4):480-482.
5. Ship AG, Weiss PR, Mincer FR, Wolkstein W. Sternal keloids: successful treatment employing surgery and adjuvant radiation. *Ann Plast Surg*. 1993;31(6):481-487.
6. Park TH. New pressure device, "Magsil," as an adjuvant pressure therapy for ear keloids. *Arch Facial Plast Surg*. 2012;14(4):298-299.
7. van Leeuwen MC, van der Wal MB, Bulstra AE, et al. Intralesional cryotherapy for treatment of keloid scars: a prospective study. *Plast Reconstr Surg*. 2015;135(2):580-589.
8. Curran JN, Crealey M, Sadadcharam G, et al. Vitamin E: patterns of understanding, use, and prescription by health professionals and students at a university teaching hospital. *Plast Reconstr Surg*. 2006;118(1):248-252.
9. Burton GW, Joyce A, Ingold KU. Is vitamin E the only lipid-soluble, chain-breaking antioxidant in human blood plasma and erythrocyte membranes? *Arch Biochem Biophys*. 1983;221(1):281-290.
10. Ehrlich HP, Tarver H, Hunt TK. Inhibitory effects of vitamin E on collagen synthesis and wound repair. *Ann Surg*. 1972;175(2):235-240.
11. Palmieri B, Gozzi G, Palmieri G. Vitamin E added silicone gel sheets for treatment of hypertrophic scars and keloids. *Int J Dermatol*. 1995;34(7):506-509.
12. Nachbar F, Korting HC. The role of vitamin E in normal and damaged skin. *J Mol Med (Berl)*. 1995;73(1):7-17.
13. Sullivan D, Chung KC, Eaves FF 3rd, Rohrich RJ. The level of evidence pyramid: indicating levels of evidence in Plastic and Reconstructive Surgery articles. *Plast Reconstr Surg*. 2011;128(1):311-314.
14. Zampieri N, Zuin V, Burro R, et al. A prospective study in children: Pre- and post-surgery use of vitamin E in surgical incisions. *J Plast Reconstr Aesthet Surg*. 2010;63(9):1474-1478.
15. Khoo TL, Halim AS, Zakaria Z, et al. A prospective, randomized, double-blinded trial to study the efficacy of topical tocotrienol in the prevention of hypertrophic scars. *J Plast Reconstr Aesthet Surg*. 2011;64(6):e137-145.
16. Baryza MJ, Baryza GA. The Vancouver Scar Scale: an administration tool and its interrater reliability. *J Burn Care Rehabil*. 1995;16(5):535-538.
17. Draaijers LJ, Tempelman FR, Botman YA, et al. The patient and observer scar assessment scale: a reliable and feasible tool for scar evaluation. *Plast Reconstr Surg*. 2004;113(7):1960-1965; discussion 1966-1967.
18. Price DD, McGrath PA, Rafii A, Buckingham B. The validation of visual analogue scales as ratio scale measures for chronic and experimental pain. *Pain*. 1983;17(1):45-56.
19. Perez OA, Viera MH, Patel JK, et al. A comparative study evaluating the tolerability and efficacy of two topical therapies for the treatment of keloids and hypertrophic scars. *J Drugs Dermatol*. 2010;9(5):514-518.
20. Baumann LS, Spencer J. The effects of topical vitamin E on the cosmetic appearance of scars. *Dermatol Surg*. 1999;25(4):311-315.
21. Jenkins M, Alexander JW, MacMillan BG, et al. Failure of topical steroids and vitamin E to reduce postoperative scar formation following reconstructive surgery. *J Burn Care Rehabil*. 1986;7(4):309-312.
22. Sakuraba M, Takahashi N, Akahoshi T, et al. Use of silicone gel sheets for prevention of keloid scars after median sternotomy. *Surg Today*. 2011;41(4):496-499.
23. Sakuraba M, Takahashi N, Akahoshi T, et al. Experience of silicone gel sheets for patients with keloid scars after median sternotomy. *Gen Thorac Cardiovasc Surg*. 2010;58(9):467-470.
24. Atiyeh BS. Nonsurgical management of hypertrophic scars: evidence-based therapies, standard practices, and emerging methods. *Aesthetic Plast Surg*. 2007;31(5):468-492; discussion 493-494.
25. O'Brien L, Jones DJ. Silicone gel sheeting for preventing and treating hypertrophic and keloid scars. *Cochrane Database Syst Rev*. 2013;9:CD003826.
26. Anthonissen M, Daly D, Janssens T, Van den Kerckhove E. The effects of conservative treatments on burn scars: A systematic review. *Burns*. 2016 Jan 14. pii: S0305-4179

- (15)00396-4. doi:10.1016/j.burns.2015.12.006. [Epub ahead of print]
27. Wolfram D, Tzankov A, Püzl P, Piza-Katzer H. Hypertrophic scars and keloids--a review of their pathophysiology, risk factors, and therapeutic management. *Dermatol Surg.* 2009;35(2):171-181.
  28. Oluwasanmi JO. Keloids in the African. *Clin Plast Surg.* 1974;1(1):179-195.
  29. Murray JC, Pollack SV, Pinnell SR. Keloids: a review. *J Am Acad Dermatol.* 1981;4(4):461-470.
  30. Ramakrishnan KM, Thomas KP, Sundararajan CR. Study of 1,000 patients with keloids in South India. *Plast Reconstr Surg.* 1974;53(3):276-280.
  31. Patino O, Novick C, Merlo A, Benaim F. Massage in hypertrophic scars. *J Burn Care Rehabil.* 1999;20(3):268-271; discussion 267.
  32. Shin TM, Bordeaux JS. The role of massage in scar management: a literature review. *Dermatol Surg.* 2012;38(3):414-423.
  33. Field T, Peck M, Hernandez-Reif M, Krugman S, Burman I, Ozment-Schenck L. Postburn itching, pain, and psychological symptoms are reduced with massage therapy. *J Burn Care Rehabil.* 2000;21(3):189-193.
  34. Roques C. Massage applied to scars. *Wound Repair Regen.* 2002;10(2):126-128.
  35. Aarabi S, Bhatt KA, Shi Y, et al. Mechanical load initiates hypertrophic scar formation through decreased cellular apoptosis. *FASEB J.* 2007;21(12):3250-3261.
  36. de Groot AC, Berretty PJ, van Ginkel CJ, et al. Allergic contact dermatitis from tocopheryl acetate in cosmetic creams. *Contact Dermatitis.* 1991;25(5):302-304.
  37. Fisher AA. Three faces of vitamin E topical allergy. *Cutis.* 1991;48(4):272-274.
  38. Perrenoud D, Homberger HP, Auderset PC, et al. An epidemic outbreak of papular and follicular contact dermatitis to tocopheryl linoleate in cosmetics. Swiss Contact Dermatitis Research Group. *Dermatology.* 1994;189(3):225-233.
  39. Saperstein H, Rapaport M, Rietschel RL. Topical vitamin E as a cause of erythema multiforme-like eruption. *Arch Dermatol.* 1984;120(7):906-908.
  40. Widgerow AD, Chait LA, Stals R, Stals PJ. New innovations in scar management. *Aesthetic Plast Surg.* 2000;24(3):227-234.
  41. van der Wal MB, Verhaegen PD, Middelkoop E, van Zuijlen PP. A clinimetric overview of scar assessment scales. *J Burn Care Res.* 2012;33(2):e79-87.

The Help You Need  
Is Finally  
Here.

**SMART  
BEAUTY  
GUIDE**  
BROUGHT TO YOU BY  
THE AMERICAN SOCIETY FOR  
AESTHETIC PLASTIC SURGERY

Prospects for Your Practice  
Products Patients Want  
Content You Trust

[www.smartbeautyguide.com](http://www.smartbeautyguide.com)

American Society for Aesthetic Plastic Surgery  
11262 Monarch St., Garden Grove, CA 92841-1441  
800.364.2147 • 562.799.2356